

Analyzing the Heart with EKG

An electrocardiogram (ECG or EKG) is a graphical recording of the electrical events occurring within the heart. In a healthy heart there is a natural pacemaker in the right atrium (the *sinoatrial node*) which initiates an electrical sequence. This impulse then passes down natural conduction pathways between the atria to the atrioventricular node and from there to both ventricles. The natural conduction pathways facilitate orderly spread of the impulse and coordinated contraction of first the atria and then the ventricles. The electrical journey creates unique deflections in the EKG that tell a story about heart function and health (Figure 1). Even more information is obtained by looking at the story from different angles, which is accomplished by placing electrodes in various positions on the chest and extremities. A positive deflection in an EKG tracing represents electrical activity moving toward the active lead (the green lead in this experiment).

Five components of a single beat are traditionally recognized and labeled P, Q, R, S, and T. The P wave represents the start of the electrical journey as the impulse spreads from the sinoatrial node downward from the atria through the atrioventricular node and to the ventricles. Ventricular activation is represented by the QRS complex. The T wave results from ventricular repolarization, which is a recovery of the ventricular muscle tissue to its resting state. By looking at several beats you can also calculate the rate for each component.

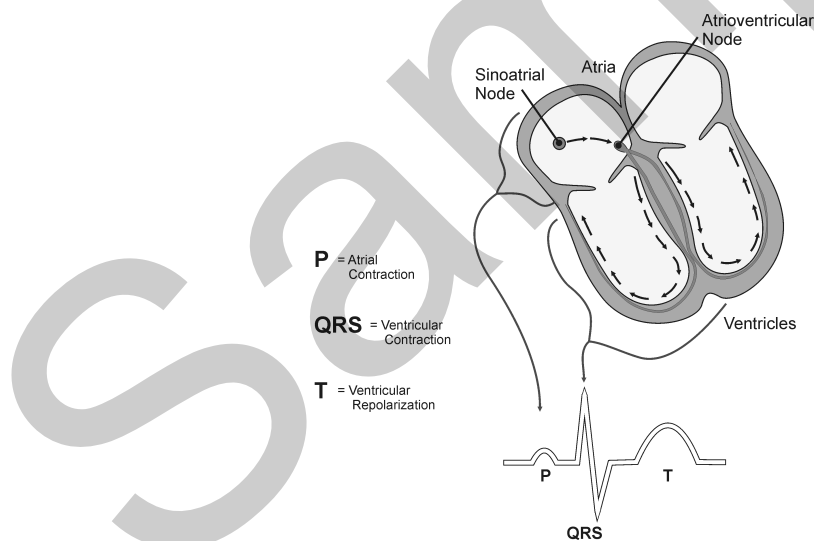


Figure 1

Doctors and other trained personnel can look at an EKG tracing and see evidence for disorders of the heart such as abnormal slowing, speeding, irregular rhythms, injury to muscle tissue (*angina*), and death of muscle tissue (*myocardial infarction*). The length of an interval indicates whether an impulse is following its normal pathway. A long interval reveals that an impulse has been slowed or has taken a longer route. A short interval reflects an impulse which followed a shorter route. If

Experiment 12

a complex is absent, the electrical impulse did not rise normally, or was blocked at that part of the heart. Lack of normal depolarization of the atria leads to an absent P wave. An absent QRS complex after a normal P wave indicates the electrical impulse was blocked before it reached the ventricles. Abnormally shaped complexes result from abnormal spread of the impulse through the muscle tissue, such as in myocardial infarction where the impulse cannot follow its normal pathway because of tissue death or injury. Electrical patterns may also be changed by metabolic abnormalities and by various medicines.

In this experiment, you will use the EKG sensor to make a five second graphical recording of your heart's electrical activity, and then switch the red and green leads to simulate the change in electrical activity that can occur with a myocardial infarction (heart attack). You will identify the different components of the waveforms and use them to determine your heart rate. You will also determine the direction of electrical activity for the QRS complex.

OBJECTIVES

- Obtain graphical representation of the electrical activity of the heart over a period of time.
- Learn to recognize the different wave forms seen in an EKG, and associate these wave forms with activity of the heart.
- Determine the heart rate by determining the rate of individual wave forms in the EKG.
- Compare wave forms generated by alternate EKG lead placements.

MATERIALS

computer
Vernier computer interface
Logger Pro
Vernier EKG Sensor
electrode tabs

PROCEDURE

Part I Standard limb lead EKG

1. Connect the EKG Sensor to the Vernier computer interface. Open the file "12 Analyzing Heart EKG" from the *Human Physiology with Vernier* folder.
2. Attach three electrode tabs to your arms, as shown in Figure 2. Place a single patch on the inside of the right wrist, on the inside of the right upper forearm (distal to the elbow), and on the inside of the left upper forearm (distal to elbow).
3. Connect the EKG clips to the electrode tabs as shown in Figure 2. Sit in a relaxed position in a chair, with your forearms resting on your legs or on the arms of the chair. When you are properly positioned, have someone click to begin data collection.

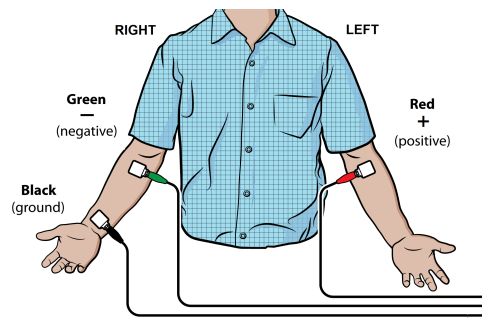


Figure 2

4. Once data collection is finished, click and drag to highlight each interval listed in Table 1. Use Figure 3 as your guide when determining these intervals. Enter the Δx value of each highlighted area to the nearest 0.01 s in Table 1. This value can be found in the lower left corner of the graph.
5. Calculate the heart rate in beats/min using the EKG data. Record the heart rate to the nearest whole number in Table 1.
6. Store this run by choosing Store Latest Run from the Experiment menu.

Part II Alternate limb lead EKG

7. Exchange the red and green EKG clips so that the green clip is now attached to the electrode tab on the left arm and the red clip is on the right arm. Sit in a relaxed position in a chair, with your forearms resting on your legs or on the arms of the chair. When you are properly positioned, have someone click to begin data collection.
8. Print or sketch the tracing for alternate limb lead placement only.

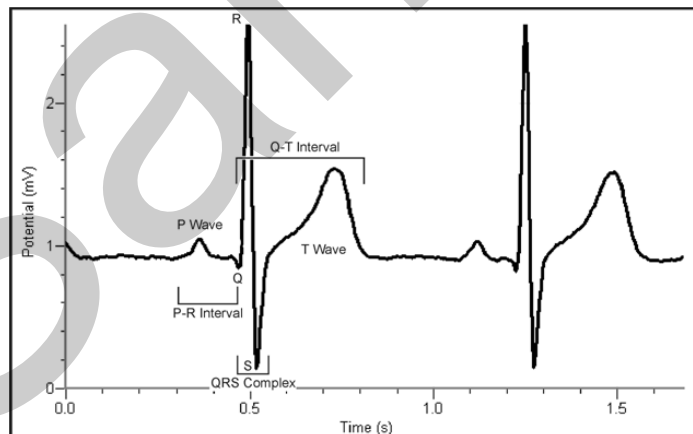


Figure 3

- **P-R interval:** time from the beginning of P wave to the start of the QRS complex
- **QRS complex:** time from Q deflection to S deflection
- **Q-T interval:** time from Q deflection to the end of the T

DATA

Table 1	
Interval	Time (s)
P-R	
QRS	
Q-T	
R-R	

Heart rate (bpm)	
------------------	--

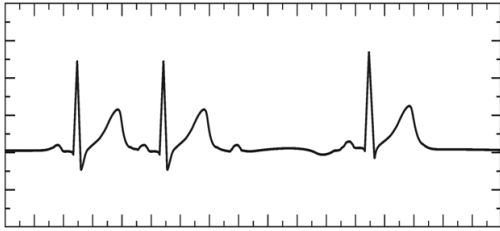
Table 2	
Standard Resting Electrocardiogram Interval Times	
P-R interval	0.12 to 0.20 s
QRS interval	less than 0.12 s
Q-T interval	0.30 to 0.40 s

DATA ANALYSIS

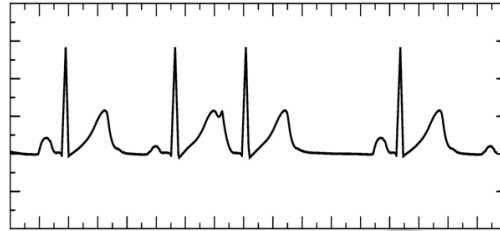
1. Remember that a positive deflection indicates electrical activity moving toward the green EKG lead. Examine the two major deflections of a single QRS complex (R wave and S wave) in your EKG tracing from Part I of this experiment. According to this data, does ventricular depolarization proceed from right to left or left to right? How does your tracing from Part II confirm your answer?
2. Health-care professionals ask the following questions when interpreting an EKG:
 - Can all components be identified in each beat?
 - Are the intervals between each component and each complex consistent?
 - Are there clear abnormalities of any of the wave components?

Using these questions as guides, analyze each of the following three-beat EKG tracings and record your conclusions in Table 3 (indicate presence or absence of the P wave, and whether other intervals and/or shapes are normal or abnormal).

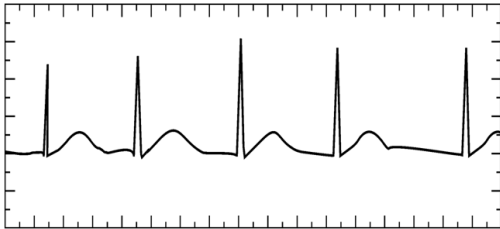a.



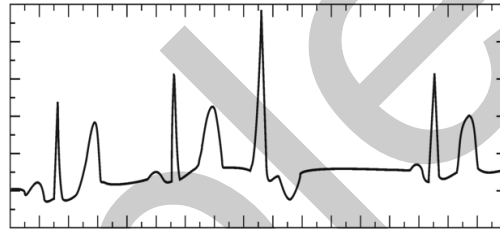
b.



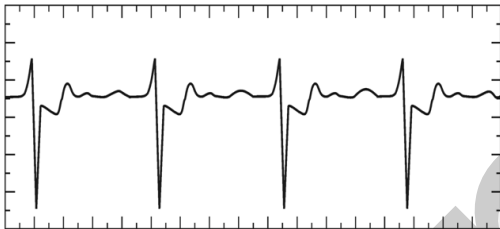
c.



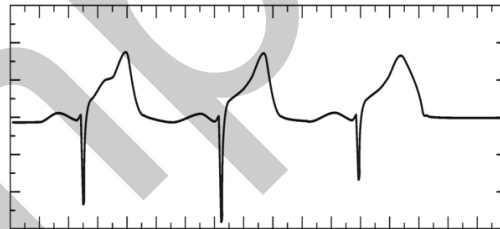
d.



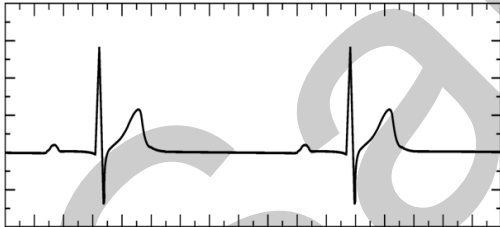
e.



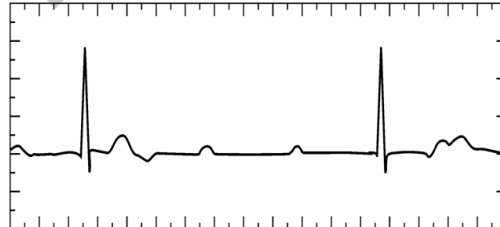
f.



g.



h.



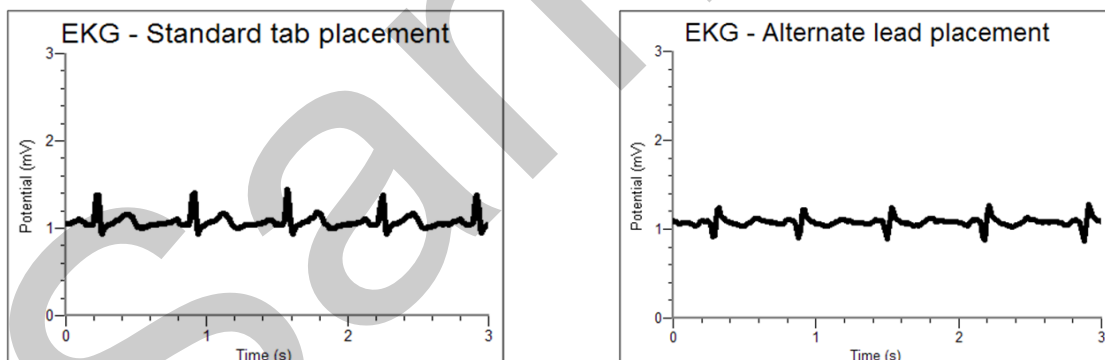
Experiment 12

Table 3											
ECG	Beat	P Wave		PR Interval		QRS Interval		QRS Shape		T Wave	
		Pres.	Abs.	Nml.	Abs./Abn.	Nml.	Abs./Abn.	Nml.	Abn.	Nml.	Abs./Abn.
a	1	X		X		X		X		X	
	2	X		X		X		X		X	
	3	X			X		X		X		X
b	1										
	2										
	3										
c	1										
	2										
	3										
d	1										
	2										
	3										
e	1										
	2										
	3										
f	1										
	2										
	3										
g	1										
	2										
	3										
h	1										
	2										
	3										

Analyzing the Heart with EKG

1. The student pages with complete instructions for data collection using LabQuest App and Logger *Pro* (computers) can be found on the CD that accompanies this book. See Appendix A for more information.
2. If the test subject's skin is oily or a lotion has been applied, scrub the area of skin where the electrode is to be attached with soap and water prior to applying the electrode.
3. Students will find that not all EKGs look alike. They should not be alarmed. Individual differences can be caused by a variety of benign conditions. Two common benign conditions that may be seen in class are premature atrial beats (as in Question 1b) and premature ventricular beats (as in Question 1d). Waveform amplitudes and shapes may also vary from student to student.
4. Table 3 is provided to allow students to methodically analyze each EKG tracing. However, in practice, reading EKGs is a visual experience. Encourage students to review the EKG tracings and be able to describe unique attributes of each tracing.
5. A cleaner signal may be obtained by disconnecting LabQuest from AC power.

SAMPLE DATA



Sample EKG data with standard and alternate limb lead placements

Table 1	
Interval	Time (s)
P-R	0.17
QRS	0.11
Q-T	0.41
R-R	0.67

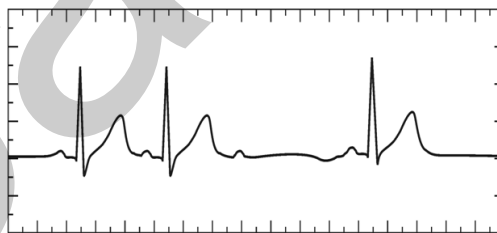
Heart rate (bpm)	90
------------------	----

ANSWERS TO THE DATA ANALYSIS QUESTIONS

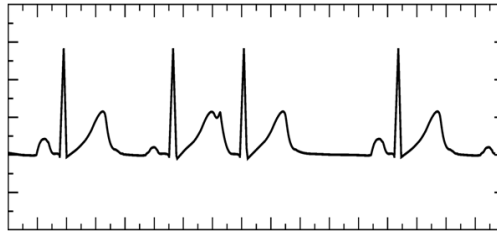
1. The initial deflection of the QRS complex in Part I of the experiment is positive, with the next deflection negative. This indicates that the initial depolarization then proceeds to the left, as shown by the negative S wave.

In Part II, the leads are switched. The initial QRS wave is negative because its depolarization is moving toward the right side of the body, this time away from the green lead. This confirms the finding in Part I of the experiment.

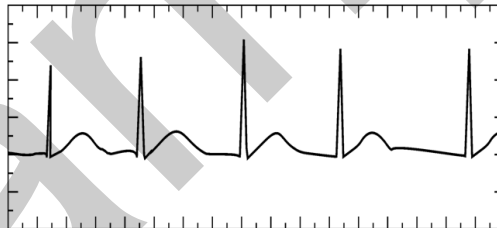
2. Following are details about each of the tracings presented in the Questions section of the student version of this lab exercise:
 - a. Second degree heart block: This is a term given to the sudden dropping of a ventricular beat (QRS complex). A normal P wave is generated, but at periodic intervals the impulse fails to reach the ventricles. This can be caused by scarring in conduction pathways or the acute injury which occurs in myocardial infarction. If this condition persists implantation of an artificial pacemaker may be considered.



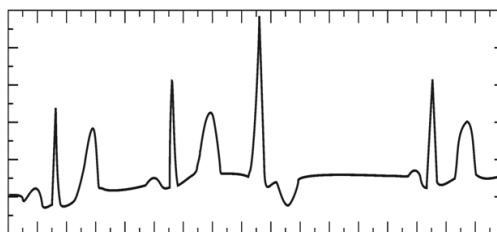
- b. Premature atrial contraction: The P wave of the third complex occurs earlier than expected and has an abnormal shape. This beat arose somewhere below the sinoatrial node and had a shorter distance to travel to the ventricles. This condition is benign and can occur more frequently in the presence of stimulants such as caffeine.



- c. Atrial fibrillation: There are no P waves seen in this tracing, indicating that the sinoatrial node is not generating electrical impulses. Instead, electrical impulses are flowing in random directions all over the atria and random impulses make their way through the atrial ventricular node down to the ventricles. This results in an irregular heartbeat, but the ventricles are contracting normally. This is a common condition at all ages but is even more common in the elderly. Since electrical activity in the atria is flowing in random directions, the atria are not contracting. This reduces the efficiency of the heart because blood must flow passively from the atria to the ventricles. The lack of contraction of the atria leads to a stagnation of blood along its walls and a higher incidence of blood clots in certain individuals. Aspirin or warfarin, a more potent anticoagulant, are used to thin the blood in many of these patients. Others may be treated by electrical cardioversion, where a shock is administered to the heart causing depolarization of all of the muscle, allowing the sinoatrial node to resume its role as a natural pacemaker.

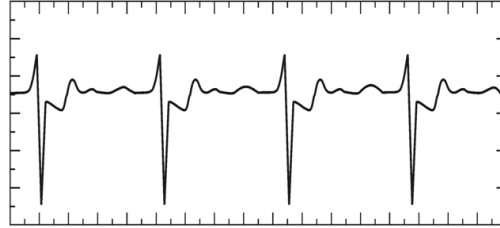


- d. Premature ventricular contraction (PVC): The wide QRS complex of beat 3 occurred as the result of an impulse arising in the ventricles. Since the impulse began in the ventricle there is no P wave, and the QRS complex is lengthened because the electricity is not following the usual conduction pathways. This condition is most often benign and may be observed in some of the students. As in premature atrial contractions, these may occur more frequently in the presence of stimulants.

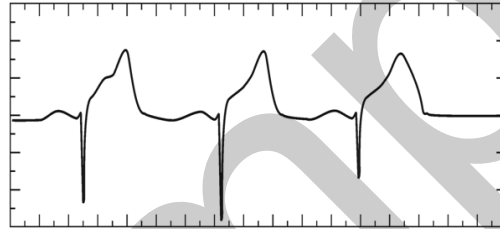


Activity 12

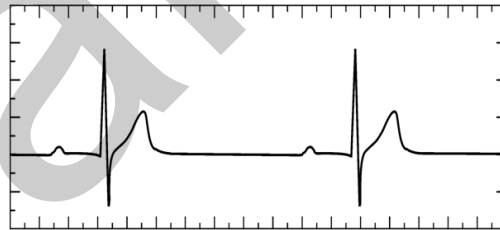
- e. Ischemia: In this tracing, the T wave is inverted as a result of abnormal repolarization of ventricular tissue. This most commonly occurs when heart muscle is not being properly supplied with blood and hence oxygen. This is the pattern often seen in patients with angina (chest pain), where partial blockages in the coronary arteries result in temporary muscle pain. After treatment with nitroglycerin or other medication the T wave will normalize.



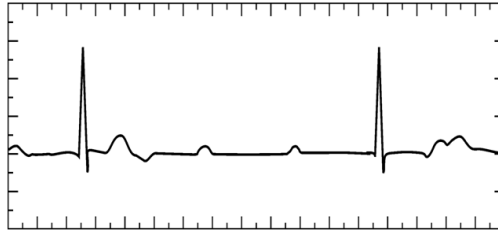
- f. Myocardial infarction: This condition, commonly known as a heart attack, results in muscle tissue damage which is severe enough to block depolarization in that tissue. Electrical forces follow an alternate pathway and can cause a deep Q wave and a grossly elevated and abnormal T wave.



- g. First degree heart block: The prolonged P-R interval is caused by abnormalities in the pathway from the sinoatrial node to the ventricles. This commonly occurs in the vicinity of the atrioventricular node. This condition is usually benign.



- h. Complete heart block: P waves and QRS complexes appear at normal intervals, but they are not attached to each other. In this condition the electrical impulse is completely blocked before it reaches the ventricles. The atrioventricular node takes over as the heart's pacemaker, but its intrinsic rate is slower than that of the sinoatrial node. As with second degree heart block, this can be caused by scarring in conduction pathways or the acute injury which occurs in myocardial infarction. In this case, a pacemaker is required.



Activity 12

Table 3											
ECG	Beat	P Wave		PR Interval		QRS Interval		QRS Shape		T Wave	
		Pres.	Abs.	Nml.	Abs./Abn.	Nml.	Abs./Abn.	Nml.	Abn.	Nml.	Abs./Abn.
a	1	X		X		X		X		X	
	2	X		X		X		X		X	
	3	X			X		X		X		X
b	1	X		X		X		X		X	
	2	X		X		X		X			X
	3	X			X	X		X		X	
c	1		X		X	X		X		X	
	2		X		X	X		X		X	
	3		X		X	X		X		X	
d	1	X		X		X		X		X	
	2	X		X		X		X		X	
	3		X		X		X		X		X
e	1	X		X		X		X			X
	2	X		X		X		X			X
	3	X		X		X		X			X
f	1	X		X			X		X		X
	2	X		X			X		X		X
	3	X		X			X		X		X
g	1	X			X	X		X		X	
	2	X			X	X		X		X	
	3	X			X	X		X		X	
h	1	X			X	X		X			X
	2	X			X	X		X			X
	3	X			X	X		X			X